Prehistoric primates had a sweet tooth: Researchers discover cavities in 54-million-year-old fossils

September 9 2021

Micro-CT reconstruction of (A) the cranium of the extant treeshrew Tupaia gracilis (AMNH 103620) and (B) the right upper jaw fragment (P3–M3) of M. latidens (USGS 17748) with carious lesions. Enlarged second molars, with black arrows demarcating the carious lesions, demonstrate that the lesions are

positioned in the same location in both the extant and extinct taxa. This is likely due to the fact that the tongue has a difficult time reaching the occlusal basin to clean the tooth, leading to accelerated carious activity and decay in this location. Grey scale bars = 1 cm, black scale bars = 1 mm. Credit: Keegan Selig

A new U of T study has discovered the oldest known cavities ever found in a mammal, the likely result of a diet that included eating fruit.

The cavities were discovered in fossils of *Microsyops latidens,* a pointy-snouted animal no bigger than a racoon that was part of a group of mammals known as stem primates. It walked the earth for about 500,000 years before going extinct around 54 million years ago.

"These fossils were sitting around for 54 million years and a lot can happen in that time," says Keegan Selig, lead author of the study who recently completed his Ph.D. student in Professor Mary Silcox's lab at U of T Scarborough.

"I think most people assumed these holes were some kind of damage that happened over time, but they always occurred in the same part of the tooth and consistently had this smooth, rounded curve to them."

Very few fossils of *M. latidens'* body have been found, but a large sample of fossilized teeth have been unearthed over the years in Wyoming's Southern Bighorn Basin. While they were first dug up in the 1970s and have been studied extensively since, Selig is the first to identify the little holes in their teeth as being cavities.

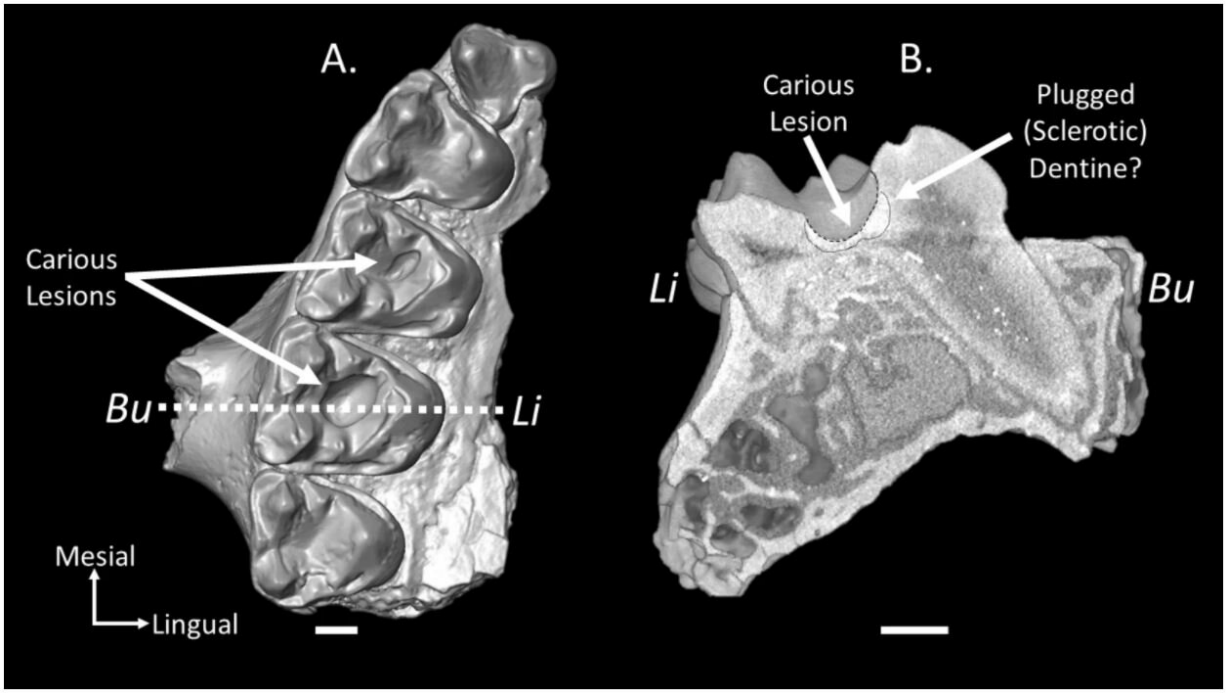

Micro-CT reconstruction of (A) the right upper jaw fragment (P3–M3) of M. latidens (USGS 17748) with carious lesions on the first and second molars and (B) a reconstruction of a slice through the caries in the second molar showing the internal morphology of the carious lesion. The slice is demarcated by the dashed line. Note that the enamel-dentine junction cannot be traced in this specimen. Identification of sclerotic dentine represents a hypothesis based on the observation of an area of higher density in the CT data at a depth that would be expected (based on the thin enamel of this taxon) to correspond to dentine. See Fuss et al.10 for another example of sclerotic dentine in a fossil primate specimen. Bu = buccal aspect, Li = lingual aspect. Scale bar = 1 mm. Credit: Keegan Selig

Cavities form when bacteria in the mouth turns foods containing carbohydrates into acids. These acids erode tooth enamel (the hard protective coating on the tooth) before eating away at dentin, the softer part of the tooth beneath the enamel. This decay slowly develops into tiny holes.

For the research, published in the journal *Scientific Reports*, Selig looked at the fossilized teeth of a thousand individuals under a microscope and was able to identify cavities in 77 of them. To verify the results, he also did micro-CT scans (a type of X-ray that looks inside an object without having to break it apart) on some of the fossils.

As for what caused the cavities, Selig says the likely culprit was the animal's fruit-rich diet. While primates would have been eating fruit for quite some time before *M. Latidens*, for a variety of reasons fruit became more abundant around 65 million years ago and primates would have started eating more of it.

Rendering by Ann Sanderson. Credit: Ann Sanderson

An interesting discovery was that out the fossil teeth studied, seven percent from the oldest group contained cavities while 17 percent of the more recent group contained cavities. This suggests a shift in their diet over time that included more fruit or other sugar-rich foods.

"Eating fruit is considered one of the hallmarks of what makes early primates unique," says Selig, whose research looks on reconstructing the diets of fossil mammals.

He adds that *M. Latidens* would naturally want to eat fruit since its full of sugar and contains a lot of energy. "If you're a little primate scurrying around in the trees, you would want to eat food with a high energy value. They also likely weren't concerned about getting cavities."

The study, which received funding from the Natural Sciences and Engineering Research Council of Canada (NSERC), not only includes the largest and earliest known sample of cavities in an extinct mammal, it also offers some clues into how the diet of *M. Latidens* changed over time. It also offers a framework to help researchers look for cavities in the fossils of other extinct mammals.

Micro-CT reconstruction of (A) the cranium of the extant treeshrew Tupaia gracilis (AMNH 103620) and (B) the right upper jaw fragment (P3–M3) of M. latidens (USGS 17748) with carious lesions. Enlarged second molars, with black arrows demarcating the carious lesions, demonstrate that the lesions are positioned in the same location in both the extant and extinct taxa. This is likely due to the fact that the tongue has a difficult time reaching the occlusal basin to clean the tooth, leading to accelerated carious activity and decay in this location. Grey scale bars = 1 cm, black scale bars = 1 mm. Credit: Keegan Selig

Selig says identifying cavities in fossils can tell us a lot about the biology of these animals. It can help figure out what they were eating and how they evolved over time based on their diet. For example, while

evolutionary changes in the structure of a jaw or teeth suggest broader changes in diet over time, cavities also offer a window into what that specific animal was eating in their lifetime.

"It might be surprising to some that cavities are not a modern phenomenon, and they certainly are not unique to only humans," he says.

Micro-CT reconstruction of (A) the cranium of the extant treeshrew Tupaia gracilis (AMNH 103620) and (B) the right upper jaw fragment (P3–M3) of M. latidens (USGS 17748) with carious lesions. Enlarged second molars, with black arrows demarcating the carious lesions, demonstrate that the lesions are positioned in the same location in both the extant and extinct taxa. This is likely due to the fact that the tongue has a difficult time reaching the occlusal basin to

clean the tooth, leading to accelerated carious activity and decay in this location. Grey scale bars = 1 cm, black scale bars = 1 mm. Credit: Keegan Selig

"I think it's interesting that here we have evidence of cavities that are more than 54 million years old, and that its teeth can tell us so much about this ancient animal that we couldn't get anywhere else."

More information: The largest and earliest known sample of dental caries in an extinct mammal (Mammalia, Euarchonta, Microsyops latidens) and its ecological implications, *Scientific Reports* (2021). DOI: 10.1038/s41598-021-95330-x , www.nature.com/articles/s41598-021-95330-x

Provided by University of Toronto

Citation: Prehistoric primates had a sweet tooth: Researchers discover cavities in 54-million-year-old fossils (2021, September 9) retrieved 19 September 2024 from https://phys.org/news/2021-09-prehistoric-primates-sweet-tooth.html