Imaging techniques can improve management and husbandry of rhinoceroses

July 10 2013

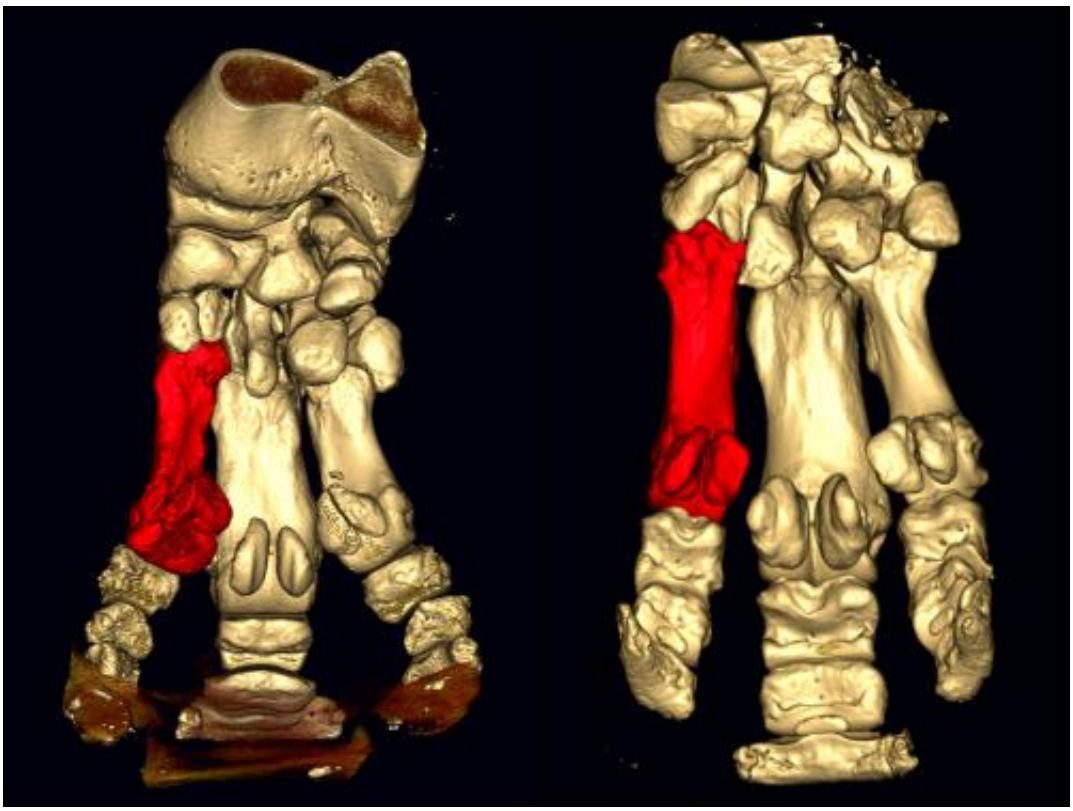

Computed tomography image of a rhinoceros foot with bone pathology (left) and without (right). Credit: Galateanu G/IZW/TOSHIBA

High-resolution computed tomography and digital radiography in captive rhinos reveal that bone pathologies in the feet of these pachyderms are highly prevalent and diverse.

Chronic foot disease is a common and severe orthopeadic disorder in captive Indian rhinoceros. It is a clinical challenge, poses a threat to the general health of the animal, affects its breeding ability and sometimes has fatal consequences. "It was surprising to find such a wide spectrum of bone pathology in terms of types and severity, affecting almost 30 % of bones at 95 sites," says Gabriela Galateanu of the Leibniz Institute for Zoo and Wildlife Research (IZW) who led this scientific study, just published online in the scientific journal *PLOS ONE.*

To shed light on chronic foot diseases and find underlying causes in rhinoceroses, an international team of scientists from Germany and three zoos from France launched a high-resolution computed tomographic study.

Zoological institutions are making a considerable effort to resolve chronic foot diseases in large mammals by continuously improving management and husbandry conditions as well as treatment procedures. In this field, hoof disorders are assumed to being confined to soft tissues only, bone pathology often being overlooked, and therefore radiographic diagnoses are rarely performed. Over the past 40 years, scientists reported only two kinds of bone pathology in three rhinoceroses (two black and one Indian rhinoceros). Foot pathology in soft tissues is widely reported in captive Indian rhinoceroses, affecting practically all breeding males from European collections. Intriguingly enough, captive elephants, who also suffer from chronic foot disease, display a wide variety of both soft tissue and bone pathologies, with over 20 osteopathologies reported to date. It has been unclear how exactly this orthopaedic disorder unfolds in these megaherbivores and what are the fundamental causes of such a limited number of reported bone pathologies in rhinoceroses. Scientists from the IZW therefore applied modern imaging techniques to investigate possible bone pathologies. They initiated a computed tomographic study, using the highest resolution available in veterinary science, followed by digital radiography. The team showed that bone

pathologies in rhinoceros feet are highly common and quite diverse.

Today, of the five extant rhinoceros species four are endangered or critically endangered and, for some of them living in captivity may be a key to population and species survival. It is therefore important that for conservation breeding purposes animals in captivity remain healthy.

"It turned out that osteopathology made no exceptions. It was encountered in both species studied, the Southern white and the Indian rhinoceros, and in animals with soft tissue tumours or with known chronic foot disease and, most surprisingly, in a white rhinoceros that showed no discernible clinical signs of foot afflictions", Robert Hermes says, rhino expert at the IZW.

This new evidence suggests that bone pathology in distal limbs is more widespread than was previously thought. The findings of this study force us to rethink of radiographic diagnosis in captive megaherbivores as a routine examination incorporated into their health management. It is highly recommended that radiographic examination of the distal limbs become a standard diagnostic tool and, ideally, also a periodic health monitoring tool, acknowledging that the first step towards a better clinical management is to elucidate the pathology involved.

The IZW supports the substantial efforts made over the last decades by zoological staff worldwide to eliminate chronic foot disease in captive megaherbivores. "We are presently working on providing zoo clinicians with practical tools for improved diagnostic imaging", Thomas Hildebrandt comments, head of the IZWs' Department of Reproduction Management.

More information: Galateanu, G. et al. (2013): One small step for rhinos, one giant leap for wildlife management - imaging diagnosis of bone pathology in distal limb. *PLOS ONE.*

dx.plos.org/10.1371/journal.pone.0068493