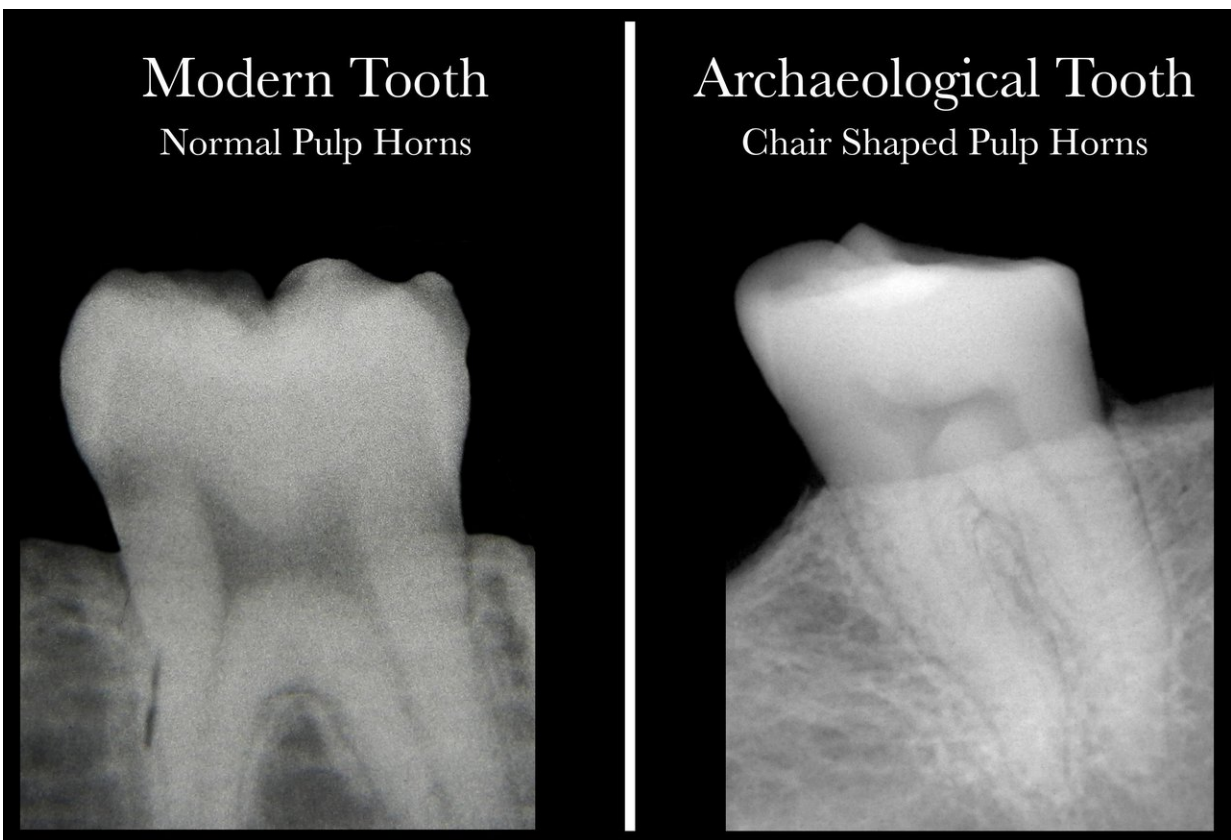


# Science meets archaeology with discovery that dental X-rays reveal Vitamin D deficiency

November 7 2017

---



Comparison of dental X-rays from patients with and without Vitamin D deficiency. Credit: McMaster University

Human teeth hold vital information about Vitamin D deficiency, a

serious but often hidden condition that can now be identified by a simple dental X-ray, McMaster anthropologists Lori D'Ortenzio and Megan Brickley have found.

Their research appears today in the *International Journal of Paleopathology*.

The researchers and their colleagues had previously discovered that human [teeth](#) hold a detailed and permanent record of serious Vitamin D deficiency, or rickets. That record takes the form of microscopic deformities in dentin, the material that makes up the mass of the tooth, and can be extremely valuable for understanding precisely when people, even those who lived centuries ago, were deprived of sunlight, the main source of Vitamin D.

The record is preserved by enamel, which protects teeth from breaking down, unlike bones, which are subject to decay.

The problem with looking for such deformities is that a tooth must be cut open to read the patterns that form a lifetime's Vitamin D record, and the supply of post-mortem teeth available for study is limited.

To avoid wasting precious specimens, the researchers went looking for a way to isolate teeth for further study. By using X-rays to study the readily observable shapes of the "pulp horns"—the dark shadow at the centre of the image of a tooth—they found a consistent, recognizable pattern that could prove helpful not only to their studies of archaeological teeth, but to living people who may not realize they are suffering from Vitamin D deficiency.

"We were looking for a non-destructive method so we wouldn't need to destroy precious archaeological material to see if there had been a deficiency," says D'Ortenzio, a PhD candidate in anthropology and lead

author of the paper. "Now we know which teeth to look at."

The pulp shape in a healthy person's tooth resembles an arch topped by two cat ears, while the pulp shape of a person who has had a severe deficiency of Vitamin D is asymmetrical and constricted, and typically looks like the profile of a hard-backed chair.

D'Ortenzio and Brickley's previous research had suggested such a recognizable pattern, and their examination of both historic and current teeth proved that X-ray images are consistent and reliable indicators of prior deficiency.

"It was a real Eureka! It wasn't just that it looked different. It was different," says Brickley, a Professor of Anthropology who holds the Canada Research Chair in the Bioarchaeology of Human Disease. "I think it's really important. It was a piece of work that aimed to look more at past individuals, but it has the potential to contribute to modern health care as well."

Since the consequences of Vitamin D deficiency can be severe - especially in terms of bone health - knowing who has had a deficiency can help identify people who may have ongoing issues in time to prevent worse damage, the researchers say. If regular dental X-rays show a problem, blood tests can confirm whether there is an ongoing deficiency.

Such evidence could be particularly valuable in the case of children whose bones are still growing, the researchers say, and spotting a problem early could head off future problems with Vitamin-D related bone deficiency.

Knowing more about ongoing Vitamin D deficiency can also help to determine what is the best balance between protecting people from harmful UV rays and making sure they get enough sun to maintain a

healthy level of the vital nutrient.

Provided by McMaster University

Citation: Science meets archaeology with discovery that dental X-rays reveal Vitamin D deficiency (2017, November 7) retrieved 23 April 2024 from <https://phys.org/news/2017-11-science-archaeology-discovery-dental-x-rays.html>

This document is subject to copyright. Apart from any fair dealing for the purpose of private study or research, no part may be reproduced without the written permission. The content is provided for information purposes only.